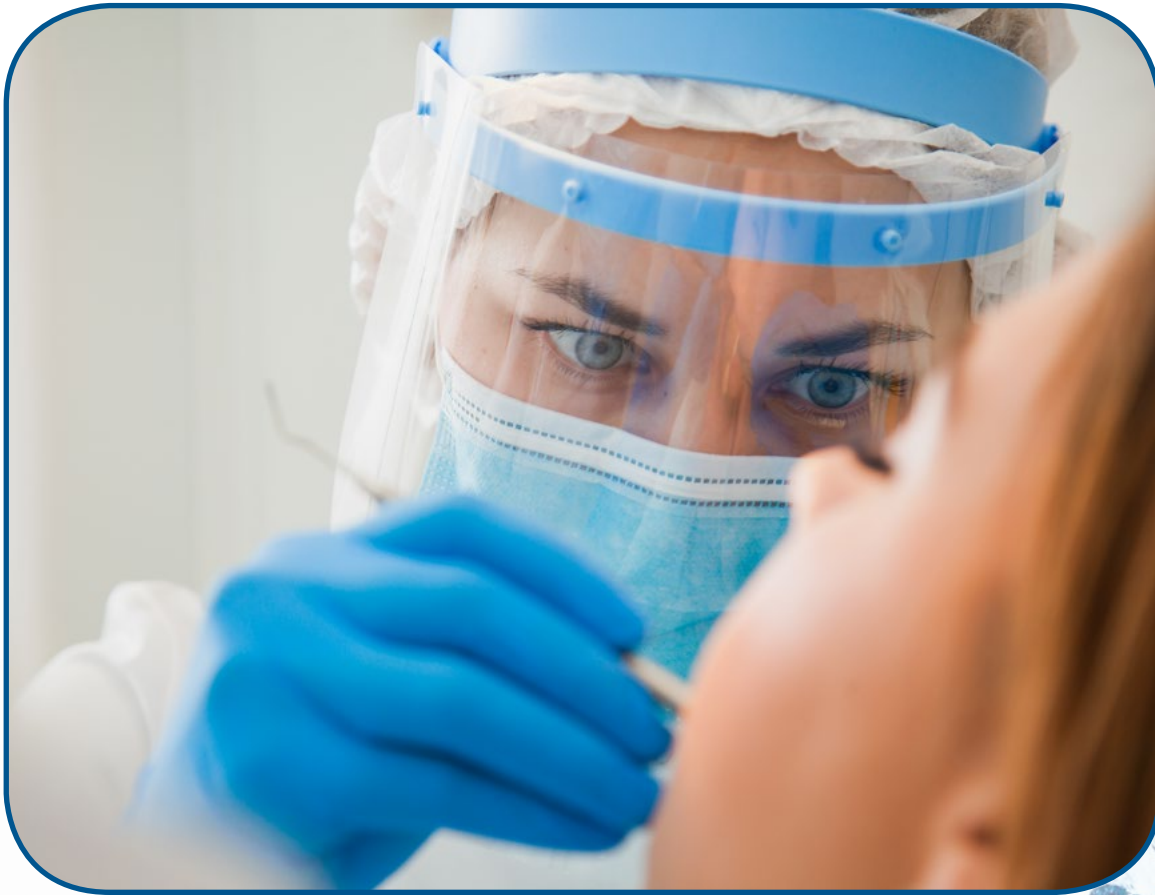

waterpik®

EFFECTIVE MAINTENANCE CARE FOR SUSTAINING DENTAL IMPLANT HEALTH

DISCLOSURE STATEMENT:

- The content for this self-study was written by Dr. Paul S. Rosen, DMD, MS, and Dr. Chandur P.K. Wadhvani, DDS, MSD.
- Water Pik, Inc. provided an honorarium for the preparation of this manuscript.
- Dr. Rosen declares no other conflicts related to this article.
- Dr. Wadhvani declares no other conflicts related to this article.

AUDIENCE:

This course is intended for dentists, dental hygienists, and dental assistants

EDUCATIONAL METHOD:

The educational method used is self-study. A post test must be submitted to receive credit.

COURSE OBJECTIVE:

To provide dental professionals with emerging information on preventive management concerning the bacterial aspects of peri-implant inflammation.

LEARNING OUTCOMES:

- Discuss the clinical signs of peri-implant mucositis and peri-implantitis
- List some of the nonbacterial causes of peri-implant inflammation
- Discuss the role that the patient plays in preventing peri-implant inflammation
- List the limitations that some of the traditional at-home oral hygiene devices may have
- Discuss the benefits that a sonic-water flossing device may provide for patients restored through dental implants

INTRODUCTION

Maintenance therapy is essential for monitoring and preserving the health and stability of successful dental implant restorations. Since root form dental implants were introduced in the United States approximately 4 decades ago, dentists have found that these medical devices are not immune to complications. A systematic review of the survival and complication rates of implant supported fixed dental prostheses, with a mean observation period of at least 5 years, reported that only 66.4% of the patients were free of any complications.¹ The most frequent biological complications over the 5-year observation period were peri-implantitis and soft tissue complications (8.5%). In this review, prosthetic complications were also noted to range from 5% for loss of retention/screw loosening up to 13.5% for veneer material fracturing. Concerning issues involving the peri-implant soft tissues, preventing these complications will help avoid implant failures. However, when a complication does occur,

it is imperative to diagnose it early and provide intervention on a timely basis.

A well-tailored maintenance program that includes diligent oral hygiene efforts on the part of the patient and routine follow-up for cleanings and examinations in the dental office is the best means to avoid complications from occurring or getting out of hand. This paper will address some of the emerging information on this subject.

PERI-IMPLANT MUCOSITIS

Throughout the evolution of dental implants, what has become apparent is that biological issues can arise that threaten implant survival. The two complications that have been focused on the most are peri-implant mucositis and peri-implantitis.² In the consensus report of the Sixth European Workshop on Periodontitis, Lindhe and Meyle³ described peri-implant mucositis as an infectious disease where the inflammatory lesion resides in the mucosa with no bone loss being evident beyond physiologic modeling/remodeling that occurred at the time of implant placement (Figure 1).

Peri-implant mucositis is clinically identified by redness and swelling of the soft tissue without radiographic bone loss. However, bleeding when probing is recognized as an essential feature.⁴ Outcomes from reports^{5,6} assessing the prevalence of peri-implant diseases over a 9–14 year period revealed that peri-implant mucositis was present in 48% of implants

(Figure 2).⁵ The traditional belief was that mucositis is a bacterially caused disease and is the precursor to patients developing peri-implantitis. Both Salvi et al.⁷ and Pontoriero et al.⁸ demonstrated a causal effect between the cessation of oral hygiene, bacterial plaque formation, and

the development of peri-implant mucositis. Salvi et al.⁷ used a biomarker, an enzyme associated with breaking down collagen known as MMP8 (which was measured from crevicular and oral fluids), indicating the presence of inflammation. The benefit of using MMP8 is that it may serve as an unbiased qualitative measure for whether peri-implant mucositis is present.

Although the decrease/elimination of this biomarker's values suggested that the resumption of oral hygiene eliminated the disease, the clinical appearance of the areas with mucositis, compared to the teeth with gingivitis, never went back to pretreatment appearance. Why this is the case is not understood.

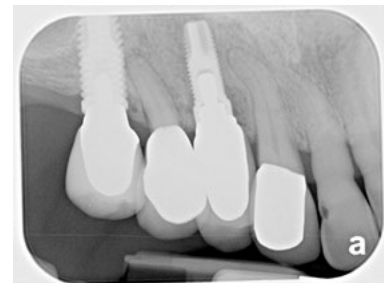

Figure 1: Radiographic bone level after case completion.

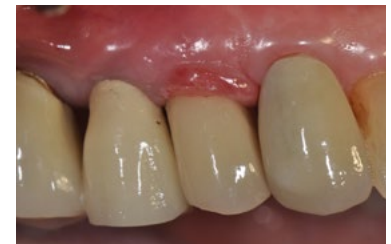

Figure 2: Peri-implant Mucositis.

It has been suggested that peri-implant mucositis is reversible with early intervention and removal of the bacterial etiology.⁹ However, treatment efforts to eliminate mucositis have fallen short of elimination—this has been the case when employing traditional mechanical therapy¹⁰ along with the addition of local and systemic chemotherapeutic adjuncts.¹¹⁻¹³ Although these approaches have demonstrated success in managing traditional gingivitis, they appear to have limited effectiveness with mucositis.

This may be explained by additional non-microbial causalities that create an inflammatory infiltrate. Examples of events that may create inflammation at the dental implant site include fretting and galling at the implant-abutment interface,^{14,15} the development of titanium metallic particles associated with the dental implant placement¹⁴ and performing specific professionally administered hygiene procedures around the dental implant.¹⁵

Bleeding on probing is an important feature of peri-implant mucositis.⁴

With fretting and galling (i.e., micromotion of the dental implant abutment during function), inflammation may be elicited by the movement itself or the resultant production of titanium granular particles. The concern with generating titanium debris in the tissue transcends simply eliciting a foreign body reaction. Suárez-López del Amo et al.¹⁴ took titanium debris that they created from dental implants and cultured the material with normal oral keratinocyte immortalized cells. These authors demonstrated that the particles/debris might contribute to the disruption of epithelial homeostasis and potentially compromise the oral epithelial barrier by damaging the cellular DNA. For a dental implant, the integrity of the surrounding sulcular epithelium is critical—this is the only defense against invasion because no collagen fibers are inserted into an implant (as is done with a tooth). Oral hygiene efforts may also create particulate titanium debris in the surrounding sulcular area of the dental implant that may impact the epithelial attachment's homeostasis. Harrel et al. demonstrated this through ultrasonic scaling of an implant whose surface is sandblasted and acid etched.¹⁵ If this particulate titanium had biofilm attached to it, the consequences could be quite devastating.

The consequence of not eliminating peri-implant mucositis could be the development of peri-implantitis, which could threaten the dental implant supported prosthesis's longevity. The need for eliminating mucositis and compliance with maintenance therapy was demonstrated in a study performed by Costa et al.¹⁶ In this study, the researchers looked at a subset of 80 patients from a prior study¹⁷ who were part of a larger population of 212 patients with dental implants. This particular subset of 80 patients was diagnosed with mucositis at baseline before their maintenance phase of treatment and was broken down into two groups. One of the two groups received preventive maintenance, and, of these individuals, 18% progressed to peri-implantitis. The outcome was far worse for the other group who experienced

no preventive maintenance. In this group, 44% progressed to peri-implantitis. Costa et al. concluded that the absence of preventive maintenance in individuals with preexisting peri-implant mucositis was associated with a high incidence of peri-implantitis. Moreover, clinical parameters, such as bleeding on peri-implant probing, probing depth, and the presence of periodontitis, were associated with a higher risk of developing peri-implantitis. This study demonstrated the importance of eliminating mucositis, giving proper instruction in oral hygiene, and regularly attending to a prescribed maintenance program for patients who have been rehabilitated with dental implants. The compromise would be attending to maintenance care at a sporadic rate. However, suboptimal outcomes for maintaining peri-implant health were demonstrated in a cohort of such patients.¹⁸

A 2017 practice-based study out of the Mayo Clinic by Hoerler et al.¹⁸ looked at a patient cohort comprising 163 patients with 941 dental implants. Overall, 55 patients with 332 implants were grouped and labeled as consistent—where the implant-supported full-arch fixed prosthesis received dental hygiene therapy biannually at a minimum, and 108 patients with 609 implants were grouped and labeled inconsistent—their dental hygiene therapy was administered at a minimum once every 3–10 years. Hoerler et al.¹⁸ found that consistent dental hygiene therapy increases the median in years in which soft tissue pathology or implant failure occurs. What was also of interest was that the material from which a dental hygiene instrument was constructed had little bearing on long-term implant survival or soft tissue pathology. In other words, specialized instruments designed for dental implant maintenance held no strategic advantage over other traditionally used instruments.

PERI-IMPLANTITIS

The term peri-implantitis was introduced in 1987 by Mombelli et al. and described the second prominent biological complication.¹⁹ The basis proposing this designation was the belief that bacteria had a causal relationship to this specific disease, where bone loss around a dental implant was beyond what would usually be seen for physiological modeling/remodeling.

For decades, dentists who have either placed or restored dental implants have pursued treatment for these two conditions predicated on the belief that these disease entities had but one etiology: bacteria. The general term “peri-implantitis” has often been applied to any implant with varying bone loss degrees beyond physiologic modeling/remodeling. In those cases where a baseline radiograph is absent, a threshold vertical distance of 2 mm from the expected marginal bone level (following remodeling post-implant placement) is the threshold for this diagnosis (Figures 3a-c).^{20,21}

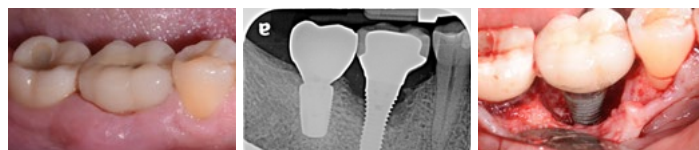

Figure 3a,b,c: Peri-implantitis around mandibular 1st molar seen clinically, radiographically and surgically.

Adherence to a professional maintenance program can increase the longevity of the implant.¹⁸

Unfortunately, as noted in a literature review by Tomasi and Derks,²² the clinical definition of peri-implantitis has differed in many studies, leading to confusion about the incidence and prevalence of this disease. It is important to note that no single diagnostic tool can, with certainty, establish a diagnosis of peri-implantitis.²³ Suppuration has been recognized as one of the diagnostic criteria for peri-implant diseases. However, its presence or absence fails to distinguish between peri-implant mucositis and peri-implantitis without other, more meaningful data.²³ Hence, it is essential that probing depths, along with bleeding on probing, be continuously recorded—when possible, in a maintenance program, along with radiographs exposed on a routine basis to recognize the disease at its earliest stages—or peri-implantitis will rapidly cause a breakdown. Moreover, there may be a need to take radiographs more frequently because the restoration may not always allow easy implant probing.²⁰

PATIENT SUPPORTIVE CARE

Although supportive care at a dental office is critical for maintaining peri-implant health, adhering to daily ongoing oral hygiene at home is also essential. For patients who have invested heavily in their implant-supported prosthesis, the question is: What to use to avoid complications?

First and foremost, the device(s) must effectively reach the site where the prosthesis emerges from the oral soft tissues to interrupt the potentially developing biofilm. One device that has demonstrated efficacy for oral hygiene challenges with implant prosthesis maintenance is a counter-rotational powered toothbrush. Truhlar et al.²⁴ performed a 6-year study with such a device. After training 85 clinical investigators at 32 dental research centers across the United States and gathering periodontal data, they evaluated 2,966 implants that had been entered into a centralized database and assessed outcomes after 24-months of observation. They noted that the counter-rotational powered toothbrush removed plaque significantly better than manual methods from all implant surfaces and at all recall intervals up to 24 months. However, tooth brushing does not reach the proximal surfaces of teeth or dental implants.

Devices such as floss and proxabrushes have traditionally been used to manage these areas. However, one of the shortcomings of flossing has been the lack of patient compliance. Reuters reported a survey related to flossing that was conducted as part of the American Academy of Periodontology's national campaign called "Love the Gums You Are With." Overall, the results showed that more than one-quarter of those surveyed said they lied to their dentists about flossing.²⁵ Another issue has been the association between remnants of dental floss being found around the neck and

coronal part of a dental implant.²⁶ Van Velzen et al. concluded that, in cases where there may be exposed rough surfaces of a dental implant, the peri-implant condition might be jeopardized by the application of dental floss.²⁶

As an alternative, interproximal brushes in combination with tooth brushing has demonstrated efficacy for interdentally cleaning teeth that exceed brushing alone or with flossing in combination with brushing,²⁷ while possibly being patient preferred.²⁸

When it comes to dental implants, Chongcharoen et al.²⁹ demonstrated that, if designed properly, interdental brushes can enhance the removal of plaque due to the higher cleansing effect on the buccal and lingual line angles, which are hard to reach.

One of the downsides for patients using interdental brushes is replacing them on a reasonably frequent basis. A welcome addition to their homecare would be the use of an ancillary aid that would not require replacement. Magnussen et al.³⁰ looked at the combined use of manual brushing with either a Waterpik® Water Flosser with the Plaque Seeker® tip or traditional flossing to reduce the bleeding on probing (BOP) index around dental implants. In a 30-day single-blinded study performed at a single center, these authors demonstrated that, after the study, 81.8% (18 of 22) implants in the water flosser group showed a reduction in BOP compared to 33.3% (6 out of 18) in the floss group—demonstrating that the use of a water flosser might be a reasonable adjunct to manual brushing to clean around a dental implant compared to traditional flossing.

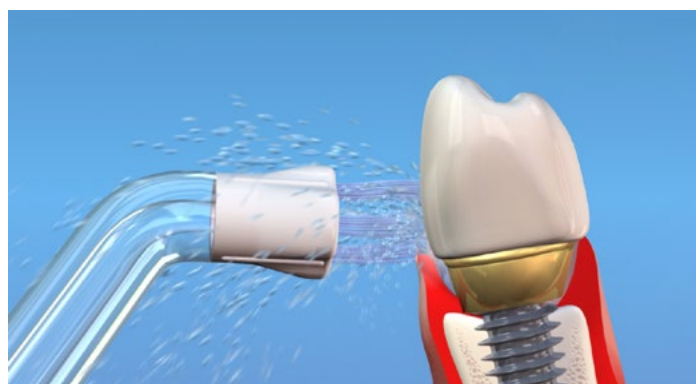

Figure 4: Plaque Seeker® Tip.

In many instances with dental implants, exposure to a rough surface may occur years after the implant's placement due to the edentulous ridge's triangular shape and the narrow dimension of the bone surrounding the dental implant. Grunder et al.,³¹ based upon Black et al.'s prior work,³² have advocated that an implant must have at least 2 mm of the bone surrounding it in all directions upon placement. However, this has not always been the case. When implant surface exposure occurs following healing or related to a bacterial insult and thin alveolar housing, plaque removal's importance becomes more challenging.

An in vitro study by Ioannidis et al.³³ looked at using an oral irrigator combined with 0.2% chlorhexidine and compared it to a sonic toothbrush with 0.2% chlorhexidine in reducing biofilms attached

to rough titanium surfaces immediately after cleaning. Following a regrowth phase of 24 hours, micro-organisms were removed equally with either device combined with a concentration of 0.2% chlorhexidine.

Given the outstanding results achieved with sonic toothbrushes, an interdental water flosser manufacturer has launched a novel product that combines a sonic toothbrush with the water flosser. In a 4-week, single-masked, 3-group parallel clinical trial comparing the novel sonic toothbrush, sonic toothbrush, or manual toothbrushing and flossing, Goyal et al.³⁵ demonstrated that the novel sonic toothbrush was significantly more effective than traditional sonic toothbrushes or standard brushing and flossing for improving oral health. It remains to be seen whether this will translate to dental implants.

There are undoubtedly several instances where hygiene may be challenged; for example, when clinicians attempt to place the implant with enough bone surrounding it, the prosthesis design may be suboptimal for hygiene to compensate for esthetic, phonetic, and functional needs (Figure 5).

Suppose a device that incorporates both sonic brushing with water flossing can overcome some of these hygiene challenges and is a patient-preferred method. In that case, it

may help reduce the incidence and prevalence of both peri-implant mucositis and subsequent peri-implantitis. As a review by Cortellini et al. pointed out, patient compliance, including plaque control and dental follow-up, must be optimal to achieve the peri-implant area's homeostasis.³⁵ Moreover, due to the continued failure to adopt other strategies for interdental cleaning, the use of water flossing unto itself would be a welcome addition if it increases compliance and reduces the incidence and prevalence of peri-implant inflammation.

Data for cleaning single implants or a bridge is very different from cleaning implants designed to retain an implant that is either removable for cleaning or nonremovable (Figure 6). The latest introduction to the Waterpik® tip designs is the Denture Retained Implant Tip (Figure 7), which allows access below the denture prosthetics and the implant interface.

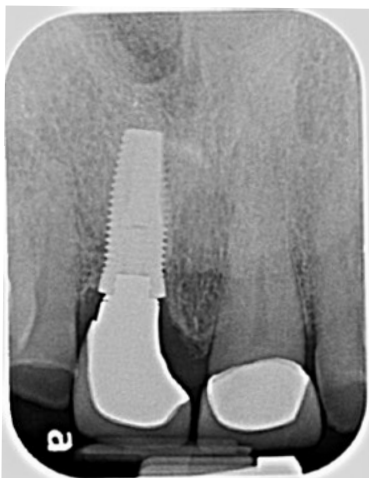

Figure 5: Although esthetic and functional, this restoration requires extra care for maintenance.

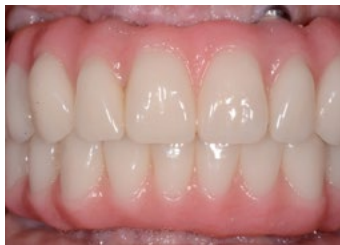

Figure 6: Screw retained maxillary and mandibular full denture.

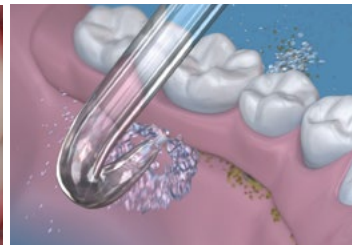


Figure 7: Denture Retained Implant Tip.

SUMMARY

The historical literature regarding the treatment of peri-implantitis suggests that no one method can be advocated, as efforts have met with a high level of failure (as evidenced by ongoing disease progression).³⁶ Although recent efforts demonstrate greater success for effective peri-implantitis management,³⁷⁻³⁹ nevertheless, were patients to perceive that their investment into their dental implant care might end badly, it could be quite emotionally devastating for them.⁴⁰ Hence, efforts must be made toward avoiding complications—this returns to emphasizing and educating patients on the role that maintenance plays in the longevity of their restoration—beginning with well-executed implant surgical and restorative treatment. It extends to identifying potential risks for complications, orienting the patient towards proper plaque control methods daily, and adhering to a well-tailored, professionally administered maintenance program. With all these factors considered, patients can achieve long-term success with their dental implant care.

REFERENCES

- Pjetursson BJ, Thoma D, Jung R, Zwahlen M, Zembic A. A systematic review of the survival and complication rates of implant-supported fixed dental prostheses (FDPs) after a mean observation period of at least 5 years. *Clin Oral Implants Res* 2012;23 (Suppl. 6):22-38.
- Mombelli A. Microbiology and antimicrobial therapy of peri-implantitis. *Periodontology* 2000. 2002;28:177-89.
- Lindhe J, Meyle J. Peri-implant diseases: consensus report of the sixth European workshop on periodontology. *J Periodontol*. 2008;35(Suppl 8): 282-285.
- Berglundh T, Armitage G, Araujo MG, et al. Peri-implant diseases and conditions: consensus report of workgroup 4 of the 2017 world workshop on the classification of periodontal and peri-implant diseases and conditions. *J Periodontol*. 2018;89 (Suppl 1):S313-S318.
- Fransson C, Lekholm U, Jemt T, Berglundh T. Prevalence of subjects with progressive bone loss at implants. *Clin Oral Implants Res*. 2005;16:440-446.
- Roos-Jansåker AM, Lindahl C, Renvert H, Renvert S. Nine- to fourteen-year follow-up of implant treatment. Part II: presence of peri-implant lesions. *J Clin Periodontol*. 2006;33:290-295.
- Salvi GE, Aglietta M, Eick S, Sculean A, Lang NP, Ramseier CA. Reversibility of experimental peri-implant mucositis compared with experimental gingivitis in humans. *Clin Oral Implants Res*. 2012;23:182-190.
- Pontoriero R, Tonelli MP, Carnevale G, Mombelli A, Nyman SR, Lang NP. Experimentally induced peri-implant mucositis: a clinical study in humans. *Clin Oral Implants Res*. 1994;5:254-259.
- Lang NP, Berglundh T, Working group 4 of the seventh European workshop on Periodontology. Peri-implant diseases: where are we now? Consensus of the seventh European workshop on periodontology. *J Clin Periodontol*. 2011 Mar;38:178-81.
- Renvert S. Non-surgical treatment of peri-implant mucositis and peri-implantitis: a literature review. *J Clin Periodontol*. 2008 Sep;35(Suppl):305-315.
- Heitz-Mayfield LJ, Salvi GE, Botticelli D, et al. Anti-infective treatment of peri-implant mucositis: a randomised controlled clinical trial. *Clin Oral Implants Res*. 2011;22:237-241.
- Hallström H, Persson GR, Lindgren S, Olofsson M, Renvert S. Systemic antibiotics and debridement of peri-implant mucositis: a randomized clinical trial. *J Clin Periodontol*. 2012;39:574-581.
- Schwarz F, Becker K, Sager M. Efficacy of professionally administered plaque removal with or without adjunctive measures for the treatment of peri-implant mucositis: a systematic review and meta-analysis. *J Clin Periodontol*. 2015;42(Suppl. 16): S202-S213.
- Suarez-Lopez del Amo F, Rudek I, Wagner VP, et al. Titanium activates the DNA damage response pathway in oral epithelial cells: a pilot study. *Int J Oral Maxillofac Implants*. 2017;32:1413-1420.
- Harrel SK, Wilson TG, Pandya M, Diekwisch TGH. Titanium particles generated during ultra-sonic scaling of implants. *J Clin Periodontol*. 2019;90(3):241-246.
- Costa FO, Takenaka-Martinez S, Cota LOM, Ferreira SD, Silva GLM, Costa JE. Peri-implant disease in subjects with and without preventative maintenance: a 5-year follow-up. *J Clin Peri-odontol*. 2012; 39: 173-181.
- Ferreira SD, Silva GLM, Costa JE, Cortelli JR, Costa FO. Prevalence and risk variables for peri-implant disease in Brazilian subjects. *J Clin Periodontol*. 2006;33:929-935.
- Hoerler SB, Nietz SK, Zook VL, et al. Consistency of dental hygiene therapy utilizing various dental hygiene instrumentation and its effect on peri-implant health and survival of dental implants: a retrospective study. *Int J Oral Maxillofac Implants*. 2017;32:1371-1376.
- Cortellini S, Favril C, De Nutte M, Teughels W, Quirynen M. Patient compliance as a risk factor for the outcome of implant treatment. *Periodontol* 2000. 2019;81(1):209-225.
- Peri-implant mucositis and peri-implantitis: a current understanding of their diagnoses and clinical implications. *J Periodontol*. 2013;84(4):436-43.
- Schwarz F, Derks J, Monje A, Wang HL. Peri-implantitis. *J Periodontol*. 2018;89 Suppl 1:S267-S290.
- Tomasi C, Derks J. Clinical research of peri-implant diseases – quality of reporting, case definitions and methods to study incidence, prevalence and risk factors of peri-implant diseases. *J Clin Periodontol* 2012;39(Suppl. 12):207-223.
- Wadhvani CPK. ed. Cementation in dental implantology. Berlin: Springer Medical; 2015.
- Truhlar RS, Morris HF, Ochi S. The efficacy of a counter-rotational powered toothbrush in the maintenance of endosseous dental implants. *J Am Dent Assoc*. 2000;131(1):101-7.
- Gumpert K. One-fourth of Americans lie to dentists about flossing. <https://www.scientificamerican.com/article/one-fourth-of-americans-lie-to-dentists-about-flossing/>
- Van Velzen FJJ, Lang NP, Schulten EAJM, ten Bruggenkate CM. Dental floss as a possible risk for the development of peri-implant disease: an observational study of 10 cases. *Clin Oral Impl Res*. 2016;27:618-621.
- Worthington HV, MacDonald L, Piricic T, et al. Home use of interdental cleaning devices, in addition to toothbrushing, for preventing and controlling periodontal diseases and dental caries. *Cochrane Database of Systematic Reviews*. 2019;4(4):CD012018.
- Kiger RD, Nylund K, Feller RP. A comparison of proximal plaque removal using floss and interdental brushes. *J Clin Periodontol*. 1991;18(9):681-4.
- Monje A, Wang HL, Nart J. Association of preventive maintenance therapy compliance and peri-implant diseases: a cross-sectional study. *J Periodontol*. 2017;88:1030-1041.
- Chongcharoen N, Lulic M, Lang NP. Effectiveness of different interdental brushes on cleaning the interproximal surfaces of teeth and implants: a randomized controlled, double-blind cross-over study. *Clin Oral Implants Res*. 2012;23(5):635-40.
- Magnuson B, Harsono M, Stark PC, Lyle D, Kugel G, Perry R. Comparison of the effect of two interdental cleaning devices around implants on the reduction of bleeding: a 30-day randomized clinical trial. *Compend Contin Educ Dent*. 2013;34(Special Issue 8):2-7.
- Grunder U, Gracis S, Capelli M. Influence of the 3-D bone-to-implant relationship on esthet-ics. *Int J Periodontics Restorative Dent* 2005;25:113-119.
- Spray RJ, Black CG, Morris HF, Ochi S. The influence of bone thickness on facial marginal bone response: stage 1 placement through stage 2 uncovering. *Ann Periodontol* 2000;5:119-128.
- Ioannidis A, Thurnheer T, Hofer D, Sahrman P, Guggenheim B, Schmidlin PR. Mechanical and hydrodynamic homecare devices to clean rough implant surfaces – an in vitro polyspecies biofilm study. *Clin. Oral Impl. Res*. 26, 2015, 523-528.
- Goyal CR, Qaqish JG, Schuller R, Lyle DM. Comparison of a novel sonic toothbrush with a traditional sonic toothbrush and manual brushing and flossing on plaque, gingival bleeding, and inflammation; a randomized controlled clinical trial. *Compend Contin Educ Dent*. 2018; 38(Suppl. 2):14-21.
- Mombelli A, Van Oosten MAC, Church E, Lang NP. The microbiota associated with successful or failing osseointegrated titanium implants. *Oral Microbiol Immunol*. 1987;2:145-151.
- Heitz-Mayfield LJ, Mombelli A. The therapy of peri-implantitis: a systematic review. *Int J Oral Maxillofac Implants*. 2014;29(Suppl):325-45.
- Froum SJ, Froum SH, Rosen PS. A regenerative approach to the successful treatment of peri-implantitis: a consecutive series of 170 implants in 100 patients with 2- to 10-year follow-up. *Int J Periodontics Restorative Dent*. 2015;35(6):857-863.
- Rosen PS, Froum SH, Froum SJ. A rationale for post-surgical laser use to effectively treat dental implants affected by peri-implantitis: 2 case reports. *Int J Oral Maxillofac Implants*. 2020;40:561-568.
- Abrahamsson KH, Wennström JL, Berglundh T, Abrahamsson I. Altered expectations on dental implant therapy; views of patients referred for treatment of peri-implantitis. *Clin Oral Impl. Res*. 2017;28:437-442.

Images 1, 2, 3(a,b,c), 5, and 6 are courtesy of Paul Rosen, DMD, MS, Periodontist, Yardley, PA.

AUTHOR(S)

Paul S. Rosen, DMD, MS, maintains a practice limited to periodontics, surgical implant placement, and regenerative therapy in Yardley, Pennsylvania, and New York City. He is a Diplomate of the American Board of Periodontology, has academic appointments at the University of Maryland Dental School and Temple University Dental School, and is a Fellow of the American College of Dentists. Dr. Rosen is the recipient of the Master Clinician Award, one of the American Academy of Periodontology's highest honors, and the Distinguished Alumni Award for Professional Achievement from the University of Maryland Dental School. He is also known internationally due to having written over 60 articles and 5 book chapters; he also lectures regularly on advanced periodontal and dental implant treatment, focusing on cutting edge techniques and innovative products.

Dr. Chandur P.K. Wadhvani, DDS, MSD, maintains a practice in prosthodontics in Bellevue, Washington. He was awarded honors and a distinction in dental surgery from the University College London School of Dentistry and received his specialty certificate in prosthodontics and a master's degree from the University of Washington, School of Dentistry. Dr. Wadhvani is the recipient of the 2018 Distinguished Lecturer Award from the American College of Prosthodontists and has academic appointments at the University of Washington, Loma Linda University, and Oregon Health & Science University. As one of the world's leading authorities on restoring dental implants, Dr. Wadhvani lectures across the globe, teaching other dental specialists techniques he has created to improve dental care. He is the primary author of numerous scientific articles and has contributed to academic textbooks focused on groundbreaking restorative techniques.

POST TEST FOR COURSE #20-34: THE ROLE OF IN-OFFICE AND AT-HOME MAINTENANCE THERAPY FOR SUSTAINING THE HEALTH AND FUNCTION OF DENTAL IMPLANTS

- 1. An infectious disease that resides in the mucosa without bone loss describes**
 - a. Gingivitis
 - b. Peri-implant mucositis
 - c. Periodontitis
 - d. Peri-implantitis
- 2. Reported prevalence over a 9–14-year period showed peri-implant mucositis was present in ___% of implants.**
 - a. 28%
 - b. 34%
 - c. 48%
 - d. 56%
- 3. Which biomarker is associated with collagen breakdown and measured from crevicular and oral fluids?**
 - a. IL- β
 - b. CRP
 - c. TNF- α
 - d. MMP8
- 4. Which of the following are examples of events that may create inflammation at the site of the implant?**
 - a. Micromotion (fretting & galling)
 - b. Titanium metallic particles
 - c. Ultrasonic scaling
 - d. All of the above
- 5. What diagnostic measurement on its own is not helpful to distinguish between peri-mucositis and peri-implantitis?**
 - a. Suppuration
 - b. Stippling
 - c. Recession
 - d. None of the above
- 6. Which clinical parameters are important to record on a regular basis to evaluate peri-implant disease?**
 - a. Probing depth increases
 - b. Bleeding on probing
 - c. Suppuration
 - d. All of the above
- 7. What percentage of American adults admit they lie about how often they floss?**
 - a. 27%
 - b. 33%
 - c. 42%
 - d. 51%
- 8. Which device was more effective at reducing bleeding on probing around implants compared to dental floss?**
 - a. Interdental brushes
 - b. Wood sticks
 - c. Rubber tip
 - d. Water flosser

OBTAINING CONTINUING EDUCATION CREDITS

CREDITS: 2 HOURS

AGD SUBJECT CODE: 690

If you have questions about the acceptance of CE credits, please consult your state or provincial dentistry board.

RECEIVE CREDITS ONLINE BY CLICKING ON THIS LINK: [Click Here](#)

Click on this link to take the post-test and receive your CE certificate upon passing.


SCORING

To receive credits, you must correctly answer 7 of 10 questions.

RESULTS

Can be downloaded immediately.

QUESTIONS SHOULD BE SENT TO: CE@WATERPIK.COM

	PACE ACADEMY of GENERAL DENTISTRY PROGRAM APPROVAL FOR CONTINUING EDUCATION	Waterpik, Inc. Nationally Approved PACE Program Provider for FAGD/MAGD credit. Approval does not imply acceptance by any regulatory authority or AGD endorsement. 6/1/2022 to 5/31/2026. Provider ID# 210474
---	---	---

This free self-study is designed for all dental professionals – no prior skills are needed.

Waterpik®, Waterpik® (stylized), Plaque Seeker®, Pik Pocket®, Nano™ and WaterFlosser® (stylized) are trademarks of Water Pik, Inc.

PN 20200512-STD
FN 20200512STD-F AB

waterpik®